

Tridimensional Sonographic Assessment of the Female Pelvic Floor

Dr Pilar Aparisi, Radiologist, Bridget Hill, Senior Sonographer

What is the sonographic assessment of the female pelvic floor?

Ultrasound is a safe, well-established, yet technically evolving technology. There is increasing interest in using ultrasound in addition to clinical examination for the assessment of pelvic floor dysfunction. The results provided by the ultrasound assessment are an extension of what cannot be appreciated beyond the wall of the vagina. This additional information may aid diagnostic accuracy and help further management.

During the sonographic (ultrasound) examination the pelvic floor is assessed dynamically to find an explanation for pelvic symptoms such as voiding dysfunction and urinary incontinence. It can also quantify and localise pelvic organ prolapse, and if present, assess the function of a sling or mesh following surgery. It is also possible to characterise prolapse, and diagnose urethrocytocoloe, cystocoloe, rectocoloe or enterocoloe as well as uterine prolapse. The pelvis is scanned through the lower abdomen, transvaginally and also directly on the perineum. 2-Dimensional and 3-Dimensional scanning is achieved with modern ultrasound

equipment. Dynamic assessment is useful with breath holding and increased pressure in the abdomen as well as during pelvic floor contraction. An important advantage that ultrasound provides is giving instant feedback to patients.

3-Dimensional ultrasound scanning allows assessment of deep muscle structures like the puborectalis muscle. It is also possible to take measurements to assist with planning for surgery.

Indications for pelvic floor ultrasound

- Urinary incontinence
- Fecal incontinence
- Recurrent urinary tract infection
- Uterine prolapse
- Some cases of pelvic, vaginal or anal pain
- Symptoms of voiding dysfunction
- Symptoms of obstructed defaecation.
- Suspected pelvic floor dyssynergy.
- Follow-up after pelvic floor surgery

Case Study

52 year old woman with stress incontinence. These longitudinal ultrasound images were taken at rest and following valsalva when the intra-abdominal pressure is increased. They show significant descent of the leading edge of the bladder to below the symphysis pubis, descent of the bladder neck and flattening of the retrovesical angle. There is also proximal urethral rotation. The findings indicate a cystocele with proximal urethral hypermobility.

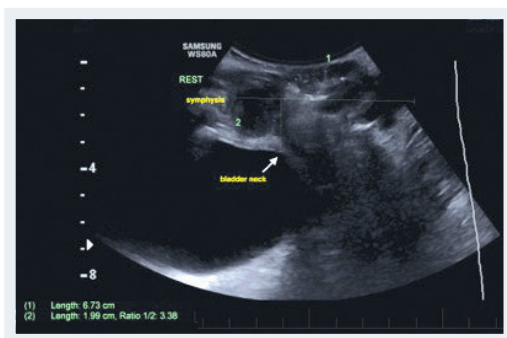


FIG 1 AT REST

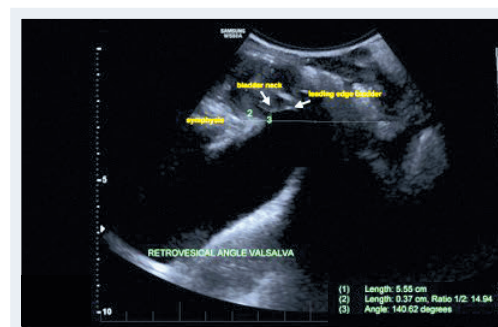


FIG 2 WITH VALSALVA

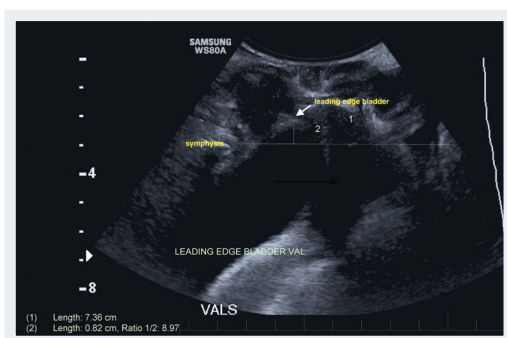


FIG 3 WITH VALSALVA

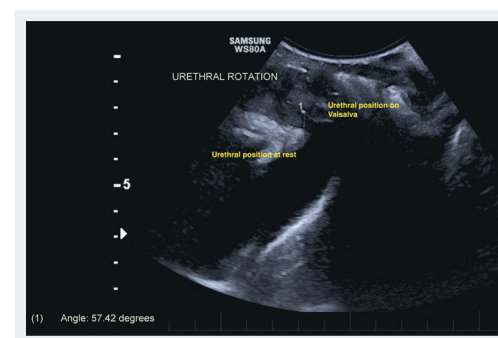


FIG 4 URETHRAL POSITION AT REST AND WITH VALSALVA

REFERENCES

Chan, L., Tse, V., The, S., Stewart, P. (2015) Pelvic Floor Ultrasound: Principles, Applications and Case Studies. <http://dx.doi.org/10.1007/978-3-319-04310-4>

Santoro, G. A., Wiczorek, A. P., Dietz, H. P., Mellgren, A., Sultan, A. H., Shobeiri, S. A., ... Bartram, C. (2011) State of the art: An integrated approach to pelvic floor ultrasonography. *Ultrasound in Obstetrics and Gynaecology*, 37, 381-396. <http://dx.doi.org/10.1002/uog.8816>


Winters, S., (2016) Imaging the pelvic floor: What's going on down there? PowerPoint presentation at the meeting of the Abdominal Radiology Group Australia & New Zealand, Perth, Australia.

Youssef, A., Montaguti, E., Sanlorenzo, O., Cariello, L., Elbadawy, E., Pacella, G., ... Rizzo, N. (2015) A new simple technique for 3-dimensional sonographic assessment of the pelvic floor muscles. *Journal of Ultrasound in Medicine*, 34, 65-72. <http://dx.doi.org/10.7863/ultra.34.1.65>

Tridimensional Sonographic Assessment of the Female Pelvic Floor is performed at our flagship practice in Milford, Auckland. The assessment is performed with the latest technology on our dedicated women's health ultrasound machine Samsung WS80.

New clinic at 209

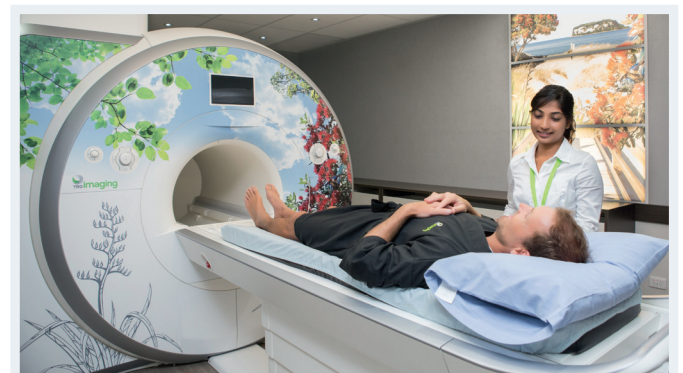New state-of-the-art facilities were shown off to invited guests at the official opening of TRG Imaging in Milford. Health Minister, The Honourable Dr Jonathan Coleman MP attended to carry out the opening formalities at the Shakespeare Road site on Thursday 19th May. The entire facility is designed to relax and reassure our patients through their radiology experience and is without doubt a first in New Zealand. With a focus on clinical and service quality, we have confidently invested in radiology healthcare, determined to make a positive contribution to our local community. Representatives from equipment providers, financial backers, medical professionals and staff converged on the stylish reception area before a tour, which highlighted the range of diagnostic services offered including x-ray, mammography, CT, MRI and ultrasound scanning.



STOP PRESS: At the recent annual Property Council Industry Awards, our flagship clinic at 209 won the achievement award in the best Healthcare buildings in New Zealand category - in simple terms, we have been voted as having one of the best Healthcare buildings in New Zealand in 2016! This is an amazing recognition of all the work that went into planning, building and now running such a special facility. It is without doubt a real credit to everyone involved.

New Siemens 3T MRI coming to Whangarei

We are proud and excited to announce the upcoming introduction of a second MRI at our clinic in Whangarei to meet the growing needs in Northland. We will be making changes to our current clinic to accommodate this very special piece of equipment and all going to plan, we should be operational by October 2016. We will keep you posted.



Meet our new Radiologists:



CARLA MORKEL MBChB, FC Rad(Diag)SA

Carla completed her medical training at the University of Stellenbosch, South Africa in 2002. She qualified as a radiologist in 2014, gaining her qualification at the University of Cape Town. After her radiology training she went on to do a year of fellowship training in Body/Abdomino-pelvic Imaging at the Foothills Medical Centre, University of Calgary, Canada. She has an interest in Body imaging and Intervention.

PRACTICE LOCATION: Whangarei



VICTORIA FRANCIS MBChB FRANZCR

Victoria completed her medical training at Otago University and her radiology training in Auckland. She is a radiologist for TRG Imaging as well as Waitemata District Health Board at North Shore and Waitakere Hospitals. Victoria completed a radiology fellowship in cancer imaging at Peter MacCallum Cancer Centre in Melbourne.

SPECIALTY: Oncology imaging. CT and MRI
PRACTICE LOCATION: Auckland



ANDREW WEST MA, MB BS, MRCP, FRCR

Andrew completed his medical and radiology training in the UK and has had considerable experience in working for the British Army both in the UK and abroad. Andrew works for TRG Imaging as well as Hawkes Bay DHB.

SPECIALTY: musculoskeletal ultrasound, Fluoroscopic guided arthrography, CT & fluoroscopic guided nerve root injections and Ultrasound and CT guided Biopsy & Drainage.
PRACTICE LOCATION: Hastings

As we continue to grow, we will soon have in excess of 30 radiologists. We would like to welcome to our team:



NICK COCHRANE MBChB, FRANZCR

Nick was born in Canada and moved to NZ in secondary school. He completed medical training in Dunedin/Wellington, and radiology training in Auckland. He then undertook two years of post-grad experience in Edmonton, Canada, followed by consultant positions in Tauranga and Auckland. Nick then returned to Canada to a University Hospital teaching post from 1999-2015 and is now back in NZ permanently, working exclusively for TRG Imaging.

SPECIALTY: body imaging (US and CT), intervention, musculoskeletal intervention.
PRACTICE LOCATION: Auckland



CHESTER CHONG MBChB, MRCS, FRCR

Chester completed his medical training in Otago and his radiology training in London and Singapore.

SPECIALTY: General radiology
PRACTICE LOCATION: Rotorua

We've opened a brand new clinic in Takanini

Where: 30 Waters Rd Takanini (Located in the main shopping area with free parking)
Hours: Monday to Friday, 8.30am to 5.00pm
Phone Us: 09 253 9611
Services: ultrasound, pregnancy imaging and x-ray

Make an appointment:
<http://www.trgimaging.co.nz/locations/request-an-appointment/>

We now accept QCard at all our Clinics

